



Microvascular Surgery: Case Report + Video

State of the Art Simultaneous Bilateral Segmental Mandibular Reconstruction using a Single Fibula Transplant: Discussion of the Surgical Steps

Todd C. Hanna^{a,*} and Dennis H. Kraus^b

SUMMARY

During last 22 years the different reports have shown successful using of vascularized single fibular transplant for a simultaneous bilateral segmental mandibular reconstruction.⁵⁻⁹ The surgeries were performed in cases of bilateral mandibular defects of different origin: 1) bilateral infected pseudoarthrosis,⁵ 2) bilateral squamous cell carcinoma of the mandible,⁶ 3) bilateral ossifying fibroma,⁷ 4) osteoradionecrosis that caused mandibular defects,^{8,9} and 5) traumatic mandibular defects.¹⁰ We present a case of a 60-year-old patient who was referred to our clinic with osteoradionecrosis of bilateral mandible, which was reconstructed using a single fibula flap. A 6-month follow-up images are presented.

© 2019 OMF Publishing, LLC. This is an open access article under the CC BY licence (<http://creativecommons.org/licenses/by-nc/4.0/>).

This is the first report of a bilateral mandibular angle functional reconstruction with a single fibula free vascularized flap. Its particular vascularization allows not only osteotomies but also ostectomy of a middle shaft.⁵

—Hervé Reychler et al, 1997
Belgium

Using of the free fibula flaps in mandibular reconstruction was popularized by Hidalgo in 1989.¹⁻⁴ Reychler et al⁵ in 1997 reported a first result of a bilateral mandibular angle functional reconstruction with a single fibula free vascularized flap. For almost twenty-two years, from 1997 to 2019, the different authors reconstructed bilateral defects on the mandible according to next etiologies:

1. Reychler et al, 1997 – for a bilateral infected pseudoarthrosis.⁵
2. Bianchi et al, 2008 – because of a rare bilateral squamous cell carcinoma of the mandible.⁶
3. Mello-Filho et al, 2008 – according to bilateral ossifying fibroma.⁷
4. Jacobson et al, 2010⁸ and Chen et al, 2018⁹ – because of an osteoradionecrosis that caused mandibular defects.
5. Ekanayake et al, 2013 – for a traumatic origin (shrapnel injury: a patient had 2 segmental defects with intact mandibular rami with condyles and intact mandibular symphyses).¹⁰

^a MD, DDS, FACS; Private Surgical Practice; Todd Hanna, MD, DDS, PC Attending; Department of Head & Neck Surgery, NY Head & Neck Institute at Lenox Hill Hospital, Northwell Health System. New York, NY, USA.

^b MD, FACS; Director, Center for Head & Neck Oncology, New York Head & Neck Institute & the North Shore-LIJ Cancer Institute. Center for Thyroid & Parathyroid Surgery. New York, NY, USA.

* Corresponding author address: 16 East 52nd Street, Suite 1101 New York, NY 10022, USA

Website: www.toddhannamdds.com

E-mail: info@toddhannamdds.com (Todd Hanna)

Instagram: [doctor.hanna](https://www.instagram.com/doctor.hanna)

Co-author's e-mail: dkraus@northwell.edu (Dennis Kraus)

Paper received 15 March 2019

Accepted 27 March 2019

Available online 31 March 2019

<http://dx.doi.org/10.23999/j.dtmp.2019.3.2>

The goal of that report is to highlight and discuss the consecutive stages of using vascularized single fibular transplant for a simultaneous bilateral segmental mandibular reconstruction (BSMR) in a 60-year-old patient who presented with osteoradionecrosis of the bilateral mandible due to radiation injury.

CASE AND DISCUSSION

A 60-year-old white male patient referred to our Clinic with a diagnosis–osteoradionecrosis of the bilateral mandible due to radiation injury (which was done for nonsurgical cancer treatment). A perfect staging classification of osteoradionecrosis^{11,12} is described by Chronopoulos et al (2018).¹³ In our case two isolated bilateral mandibular defects (according to Schrag et al systematization – Table 1) were expected.¹⁴

A bilateral mandibular segmental reconstruction (Fig 1) with a single fibular transplant for our patient was indicated. It’s that we did so while preserving the chin. Traditionally the chin would be removed along

with the other segments and muscular attachments of the tongue and lower lip, and remaining teeth, would be lost. This would severely affect speech, swallowing and esthetics. By preserving the chin we greatly preserve form function and quality of life with near base-line esthetics.

ARGUMENTS FOR VASCULARIZED BONE GRAFTS

Bae and Waters the perfectly structured arguments for different types of grafts (Table 2) made understanding of its` benefits as easy as possible.¹⁵

FIBULA FLAP ADVANTAGES & DISADVANTAGES

Shetawi and Buchbinder based on the literature and their own experience data made a clear classification of the fibula flap advantages (Table 3) and disadvantages (Table 4) in the textbook *Contemporary Oral Oncology: Oral and Maxillofacial Reconstructive Surgery* under editorship of Moni Kuriakose.¹⁶

TABLE 1. Mandibular Defects Classification Related with Components of the Defect (Schrag et al).¹⁴

Defect`s Type	Defect`s Components
Isolated	Bone only
Compound	Bone + intraoral mucosa/facial skin
Composite	Bone + intraoral mucosa + facial skin
Extensive composite	Bone + intraoral mucosa + facial skin + adjacent intraoral structure (tongue, maxilla, pharynx). Cheek volume deficit is noted

TABLE 2. Bae and Waters Systematization of the Bone Grafts Properties.¹⁵

Graft`s Type	Osteoconduction	Osteoinduction	Osteogenesis	Mechanical Strength	Vascularity
Bone marrow	+/-	+	++	-	-
Cancellous autograft	++	+	++	+	-
Cortical autograft	+	+/-	+	++	-
Vascularized	++	+	++	++	++

TABLE 3. Shetawi and Buchbinder`s Proved Fibula Flap Advantages.¹⁶

Fibula Flap Advantages
Long bone
Thick cortex
Long vascular pedicle with good caliper
Dual blood supply to the bone
Possibility of 2-team approach
Possibility of harvesting with fascia, muscle, and/or skin

TABLE 4. Shetawi and Buchbinder`s Proved Fibula Flap Disadvantages.¹⁶

Fibula Flap Disadvantages
Insufficient bone segment high
Long scar at the lower extremity
Need to graft long soft tissue defect
Weakness in toe dorsiflexion
Ankle discomfort and gait disturbance

VIRTUAL SURGICAL PLANNING

We uploaded the patient`s multislice computed tomography (CT) scans and lower limb CT angiograms to 3D Systems (Rock Hill, South Carolina, USA). The patient was planned for a bilateral mandibular osteotomy (Fig 1) – Jewer Class L bilateral defect.^{4, 17}

Virtual surgical planning calculated a need for total 145.63-mm left fibula bone segment (divided into 3 segments), using enough pedicle for anastomosis in the left mandibular defect. The length of fibular segments (Fig 2) was: 1) 46.97 to 47.72 mm – the lower fibula bone segment; 2) 50.94 mm – the middle segment, 3) and 43.81 to 46.97 mm – the upper fibula bone segment.

PREOPERATIVE TRACHEOTOMY: PRO AND CONTRA

Lapis et al (2015) in the study “Factors in successful elimination of elective tracheotomy in mandibular reconstruction with microvascular tissue” (Table 5) reported that mandibular resection and reconstruction can be performed safely without

elective tracheotomy but only in a selected group of patients.¹⁸

Statopoulos and Stassen emphasize that secure airway is critically important in the intraoperative and early postoperative period for patients undergoing head and neck cancer surgery.²⁸ A volume of the surgery upon bilateral mandibular reconstruction is similar with head–neck cancer surgery. So, it`s extremely important to secure the airway before initiated the reconstruction`s surgical steps.

Shetawi and Buchbinder are recommending having temporary tracheostomy during 5-7 days of postoperative period with a purpose to avoid airway compromise.¹⁶

Radiation therapy in the medical history of our patient counted this factor as unfavorable according to Lapis et al classification (Table 6) of potential factors influencing the decision to eliminate elective tracheotomy in head neck reconstruction.¹⁸ So, the reasoned decision to perform preoperative tracheotomy was done.

The fibula harvesting and segmental mandibular reconstruction using reconstruction plate (Fig 3) were preceded by conventional open tracheotomy, intubation, and feeding tube insertion.

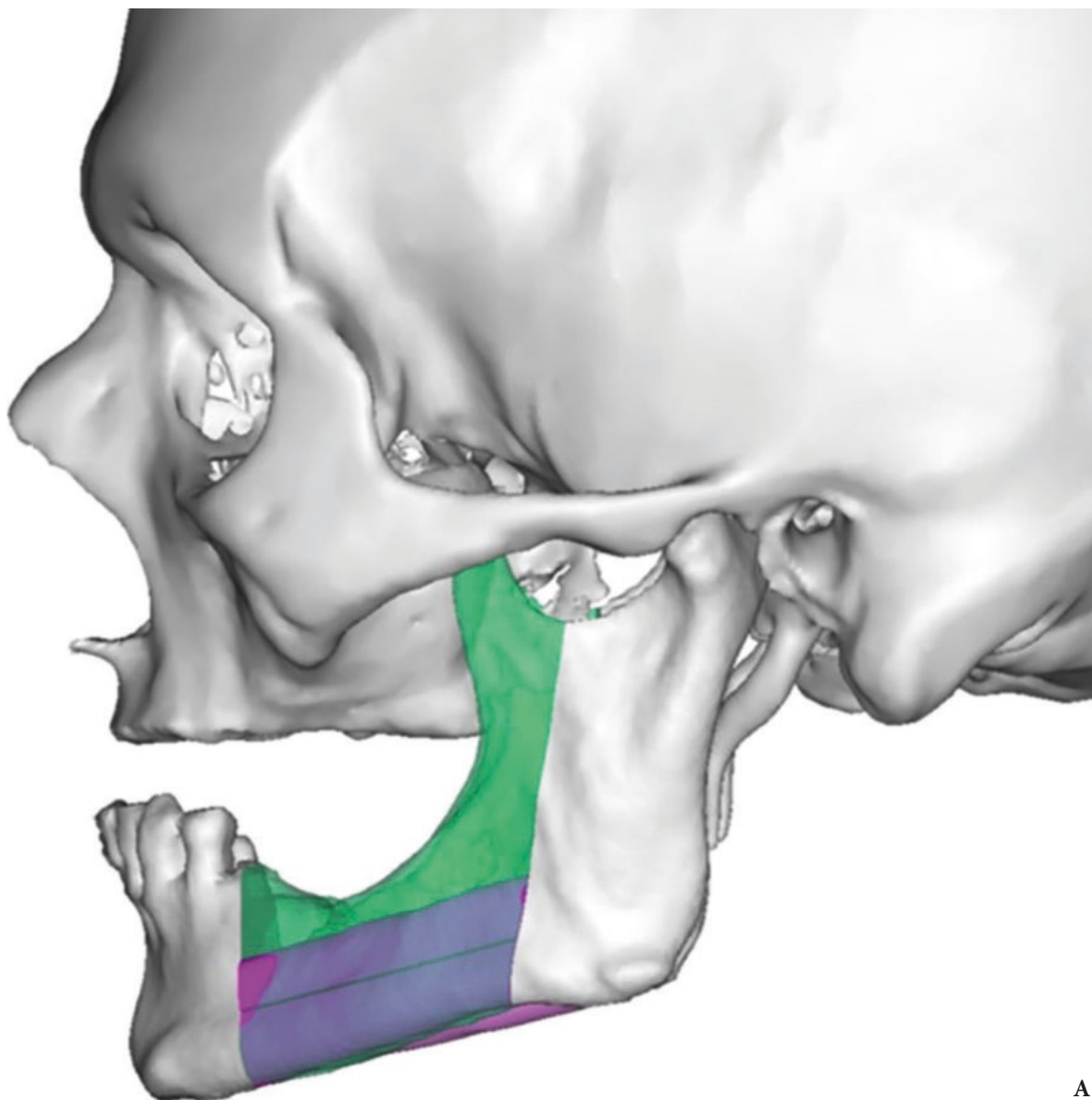


FIGURE 1. Three dimensional planning of resection site (marked with *green*) and free fibula graft (marked with *blue* and *pink*) on the left mandibular body (A). (Fig 1 continued on next page.)

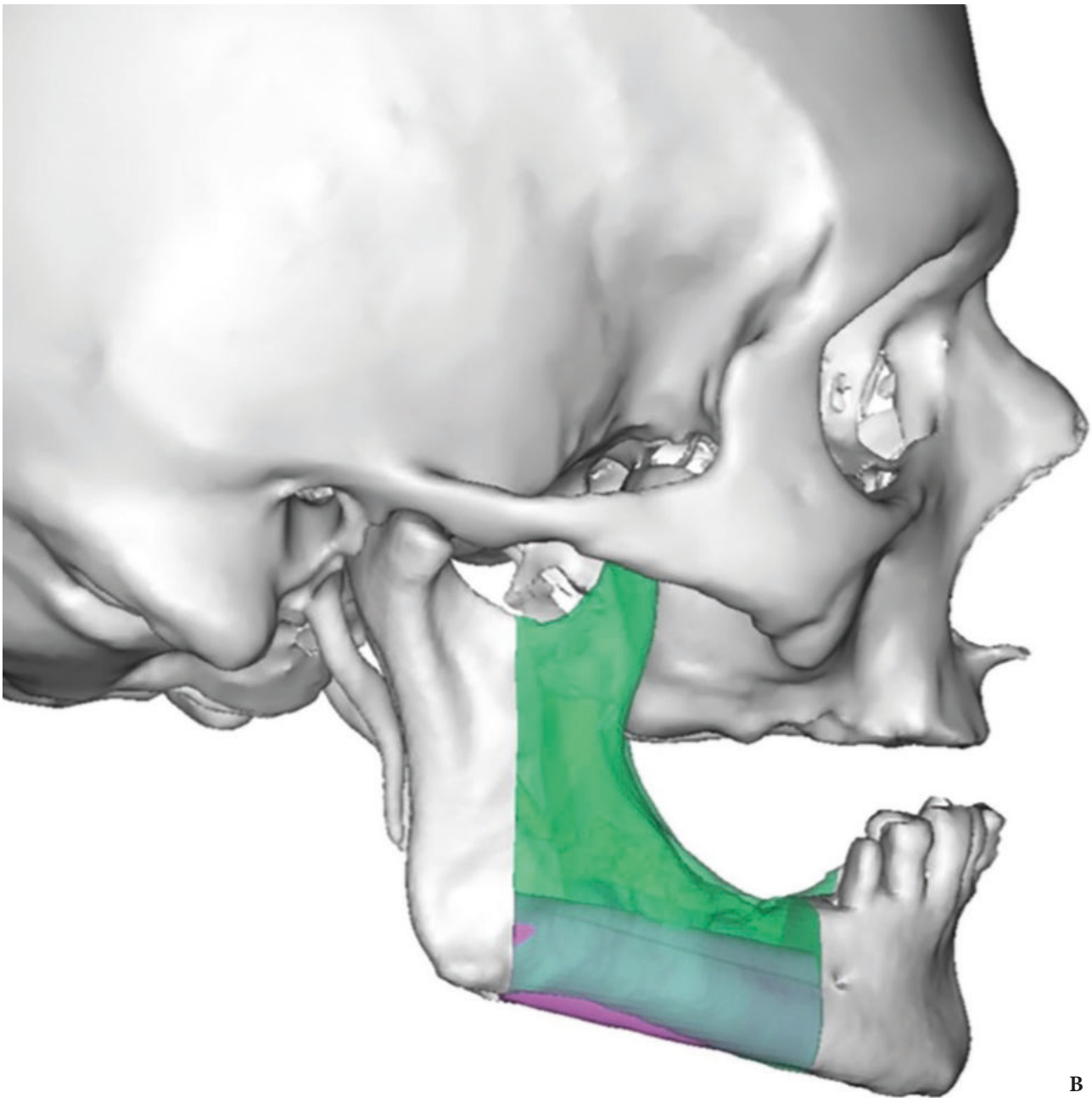


FIGURE 1 (cont'd). Three dimensional planning of resection site (marked with *green*) and free fibula graft (marked with *blue* and *pink*) on the right mandibular body (**B**). (**Fig 1 continued on next page.**)

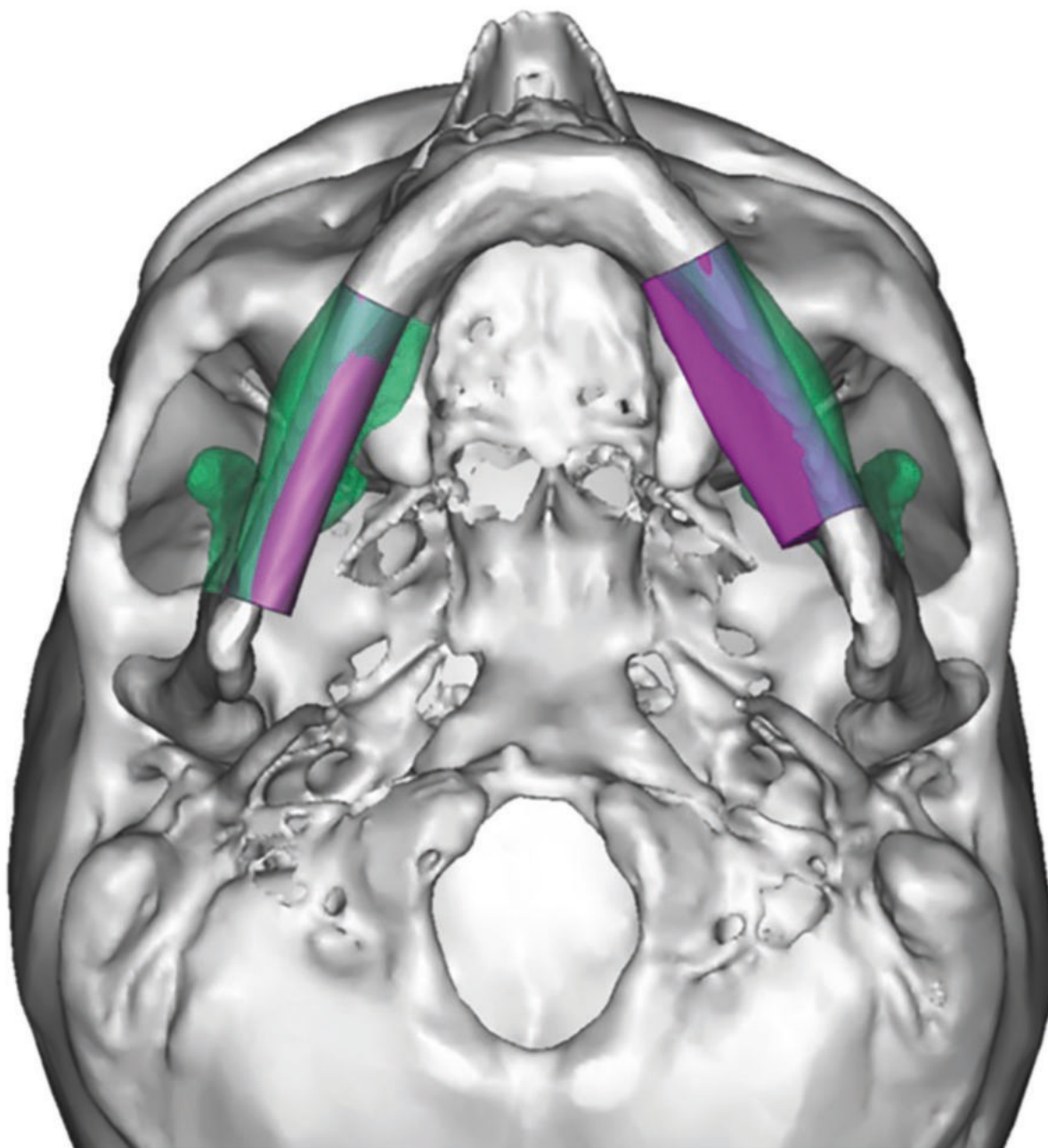


FIGURE 1 (cont'd). Axial view (C) upon three dimensional planning of resection sites (marked with *green*) and free fibula grafts (marked with *blue* and *pink*) on the bilateral mandibular sites. (Fig 1 continued on next page.)

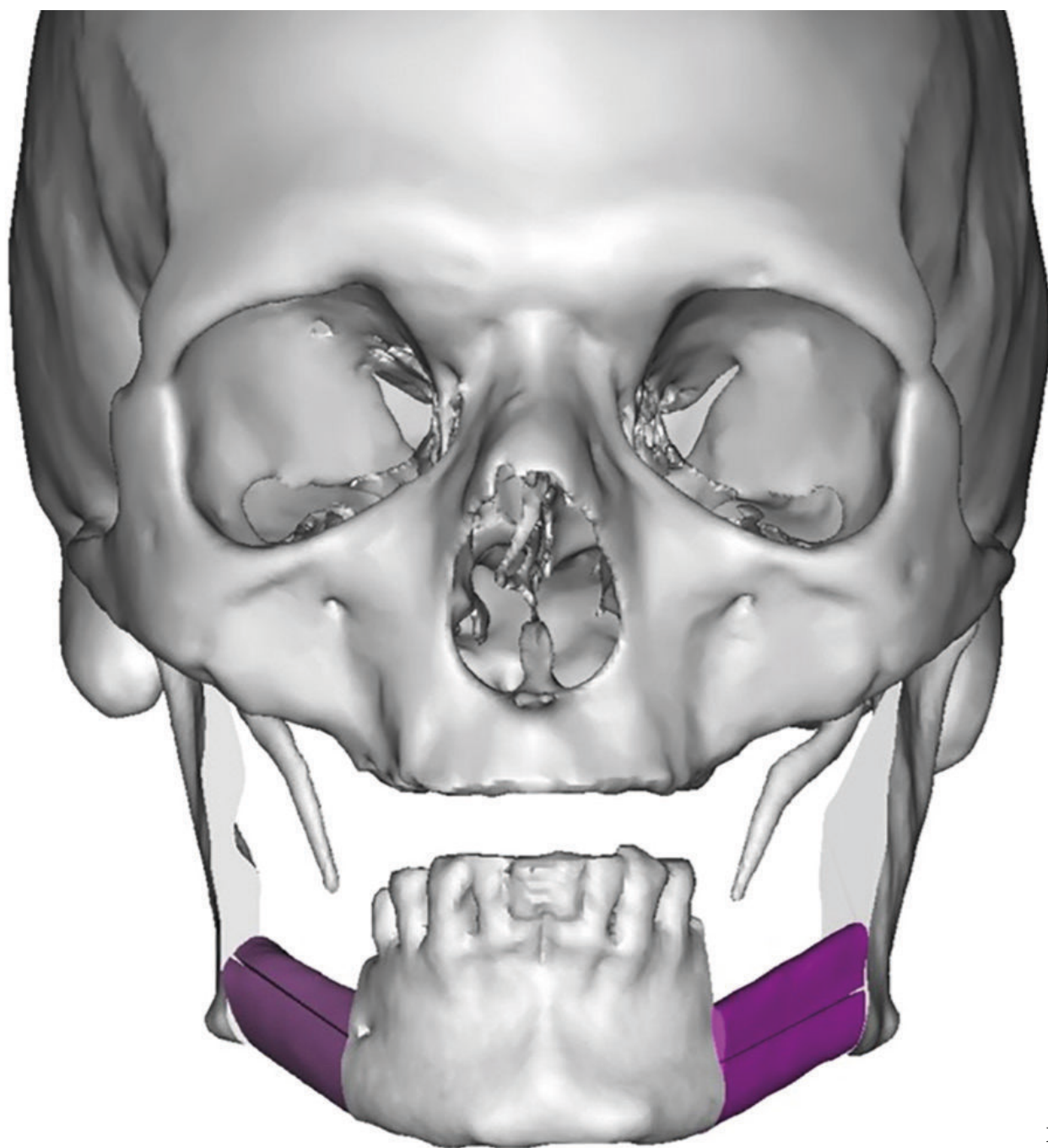


FIGURE 1 (cont'd). Anterior view (**D**) upon three dimensional planning for reconstruction with free fibula grafts (marked with *pink*) of the bilateral mandibular bodies.

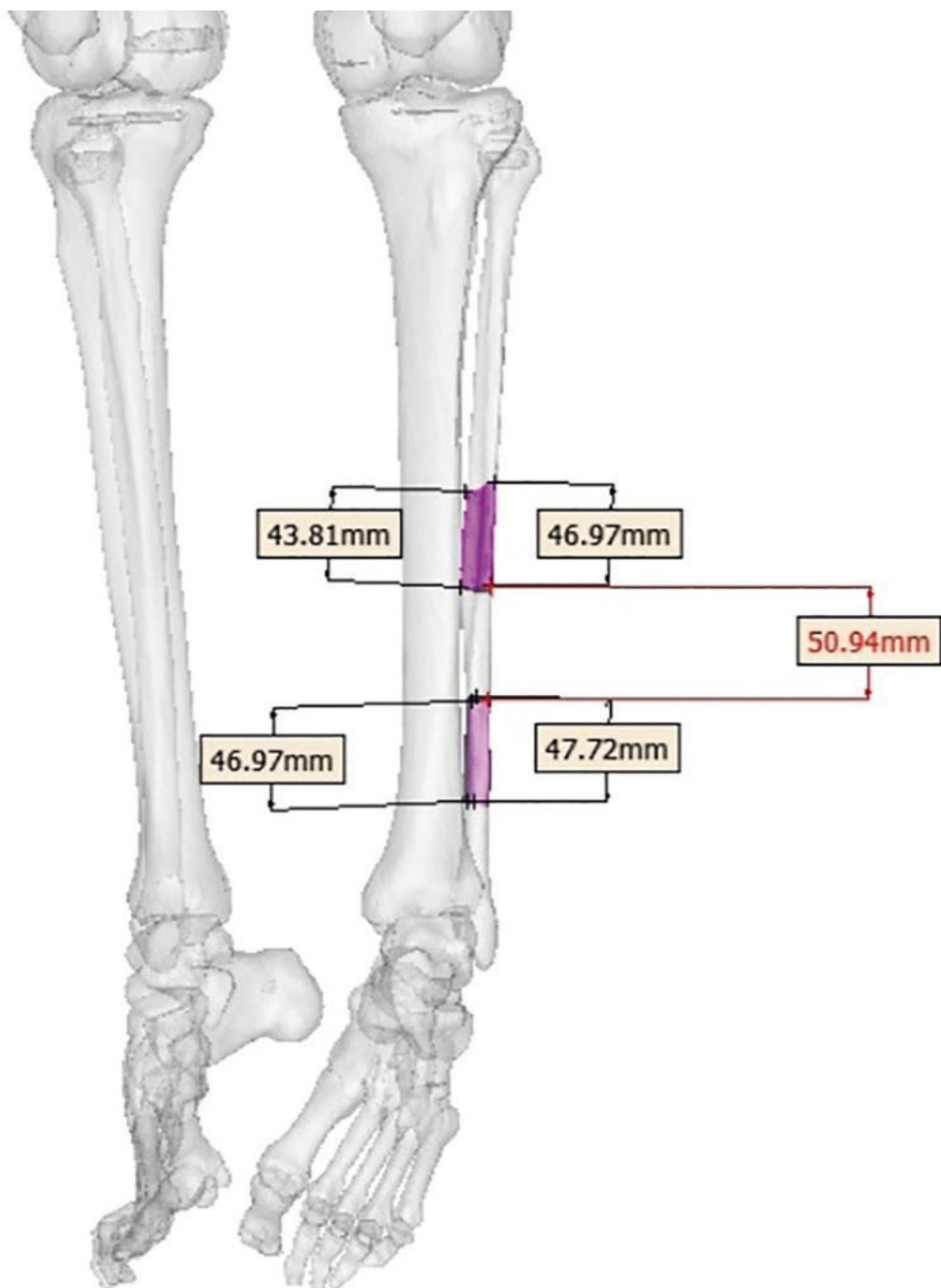


FIGURE 2. Three dimensional (3D) planning of free fibula grafts on a left fibula. The length of fibular segments: 1) 46.97 to 47.72 mm – the lower fibula bone segment (marked with *pink*); 2) 50.94 mm – the middle portion, and 3) 43.81 to 46.97 mm – the upper fibula bone segment (marked with *pink*).

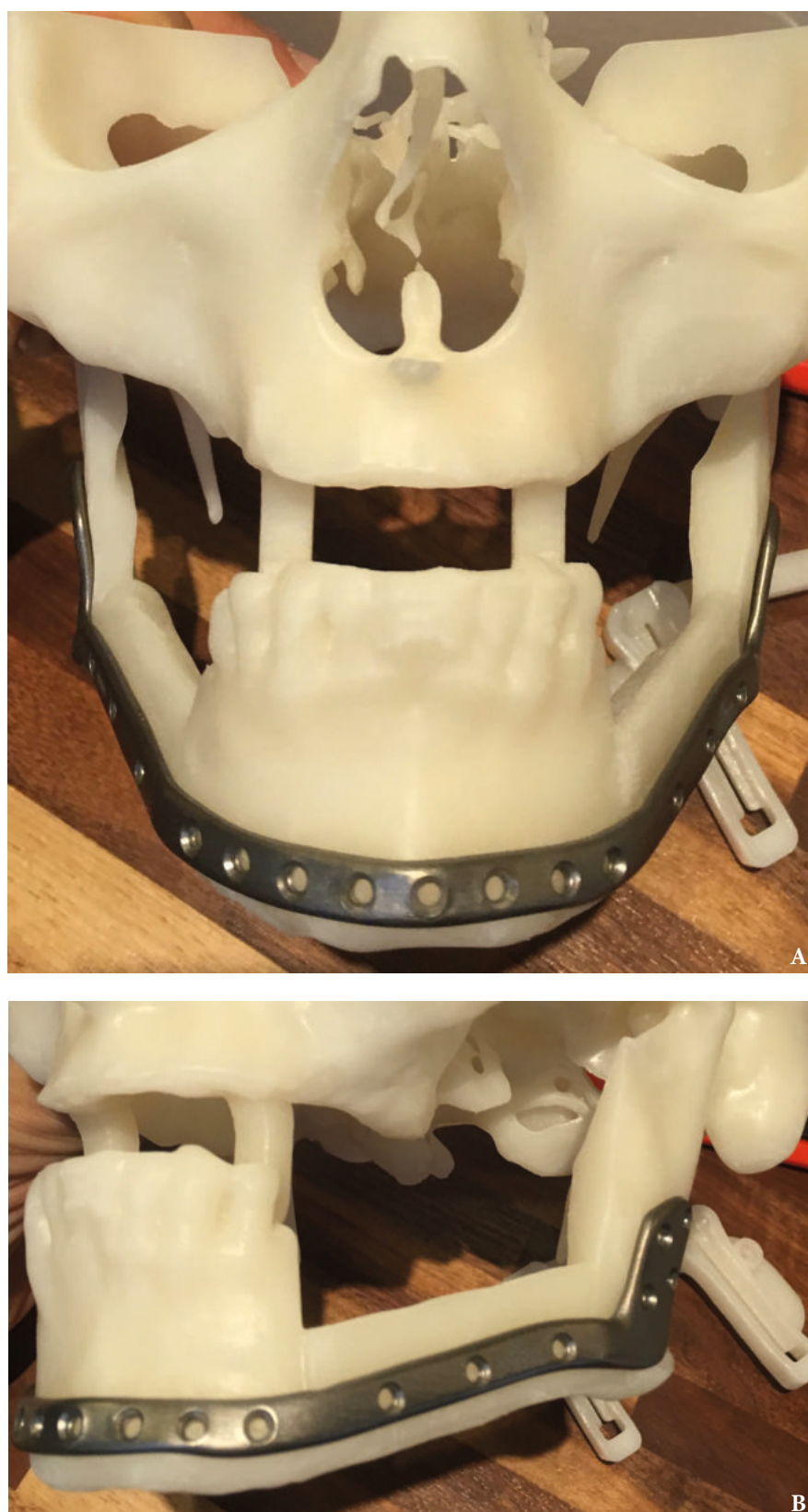

FIGURE 3. The anterior (A) and the left side view (B) of a custom titanium reconstructive plate on a stereolithographic model.

TABLE 5. Summary of Studies Investigating Omission of Elective Tracheotomy Placement for Major Oncologic Oral Cavity Resections and Reconstructions According to Lapis et al (2015).¹⁸

Source	Patients, No	Sites (%)	Free Flap Reconstructions	Patient Without Tracheotomy, No	Airway Complications (%)	Suggested Factors
Crosher et al, 1997 ¹⁹	51	Unspecified	Unknown	48	Pneumonia (2%)	Favorable: none identified Unfavorable: none identified
Lin et al, 2003 ²⁰	121	Mandible (1.7%) Maxilla (98.3%)	8	111	Pneumonia (0.9%)	Favorable: none identified Unfavorable: mandibulectomy, bulky flap reconstruction
Kruse-Losler et al, 2005 ²¹	152	Oropharynx (100%)	152	152 (preoperation) 114 (postoperation)	Not specified	Favorable: none identified Unfavorable: tumor size, posterior tumor location, pathologic chest x-ray, alcohol consumption, multimorbidity
Cameron et al, 2009 ²²	148	Mandible (31.4%) Oropharynx (14.3%) Other oral orcutaneous site (54.3%)	46 ^a	103	Aspiration pneumonia (1.4%)	Favorable: none identified Unfavorable: preoperative radiotherapy
Coyle et al, 2012 ²³	55	Mandible (47.3%) Other oral site (52.7%)	55	55	Pneumonia (9.1%)	Favorable: none identified Unfavorable: none identified
Brickman et al, 2013 ²⁴	143	Maxilla (100%)	143	79	Pneumonia or acute respiratory distress syndrome (4.2%) Aspiration (0.7%) Pneumothorax (0.7%)	Favorable: none identified Unfavorable: Pulmonary disease
Coyle et al, 2013 ²⁵	100	Mandible (45%) Other oral site (55%)	100	50	Pneumonia (24%)	Favorable: none identified Unfavorable: none identified
Meerwein et al, 2014 ²⁶	40	Oral cavity (47.5%) Other (52.5%)	40	23	None (0%)	Favorable: none identified Unfavorable: none identified
Moubayed et al, 2014 ²⁷	66	Mandible (100%)	66	66	Airway obstruction (1.5%) Aspiration pneumonia (3.0%)	Favorable: benign pathologic findings Unfavorable: tongue/pharynx soft-tissue defects, bilateral parasymphyseal defects, concurrent neck dissection
Lapis et al, 2015 ¹⁸	15	Mandible (100%)	15	15	None (0%)	Favorable: lateral defect, limited soft-tissue involvement, younger patients. Unfavorable: history of treatments (surgery, radiation)

^a46 radial forearm free flaps are identified; but, the co-authors list an additional undifferentiated combination of forty-nine pedicle and free flaps.²²

TABLE 6. Lapis et al Classification of Potential Factors Influencing the Decision to Eliminate Elective Tracheotomy in Head Neck Reconstructions.¹⁸

Favorable/ Unfavorable/Unknown	Potential Factors
Favorable	Normal upper airway anatomy
	Lateral defects
	Primary osseous pathologies with limited soft-tissue involvement
	Length of mandibular defect is not a limitation
Unfavorable	Difficult airway, trismus
	Extensive soft-tissue defects
	Oropharyngeal and posterior oral cavity defects
	History of radiotherapy
	Active pulmonary disease
Unknown	Bilateral central mandibular defects
	Age

The surgery was done under general anesthesia. First, a bilateral segmental mandibular osteotomy was performed removing radiation injured bone tissue. Then, we used the fibula approach well described in the **Wolff** and **Hölzle** masterpiece *Raising of Microvascular Flaps: A Systematic Approach*.²⁹ The harvesting of the fibula grafts were performed by implementing classic technique for harvesting fibula osteocutaneous transplant using CAD-CAM generated osteotomy guides (Fig 4). **Video** (Supplemental Video Content) demonstrates surgical stages: cutting of the fibula grafts, harvesting of the segmented grafts from left fibula. Video is available in the page of the full-text article on dtjournal.org and in the YouTube channel, available at https://youtu.be/_Tv8Cbt-HCA. Total video's duration: 1 min 13 sec. Video includes remarks of a surgeon (Todd Hanna).

RECONSTRUCTION PLATE VERSUS MINI-PLATES

Among many surgeons by 2018 there was the great number of discussions in recommendation what type of the titanium plates is better to use in cases of mandibular reconstructions. Voices from different continents and institutions argued about superior role: 1) some of the reconstruction plate^{30, 31} and 2) some of the mini-plates^{32, 33} upon different types of defects` (**Jewer** et al¹⁷) mandibular reconstruction.

Findings of **Park** et al, 2018³⁴ putted a reasoned

end to this question. As their precise study (8 reconstruction models with biomechanical stability analysis) support the use of a reconstruction plate for stable fixation upon mandibular reconstructions.³⁴ The mini-plates generate substantially greater levels of stress in majority scenarios and are a less preferable option that has more percentage to fail in the long-term follow-up period.³⁴

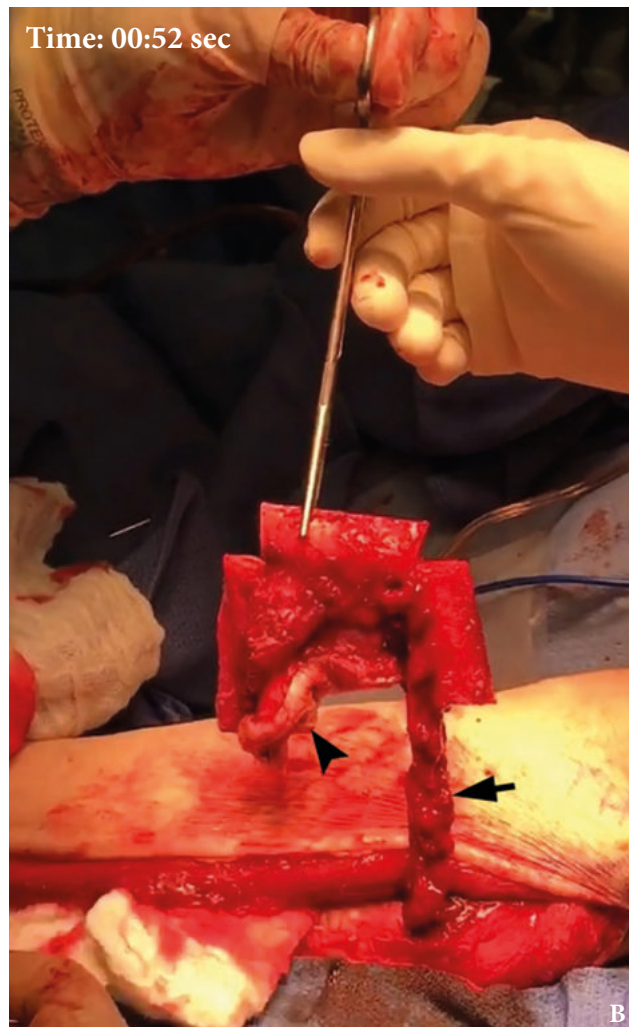
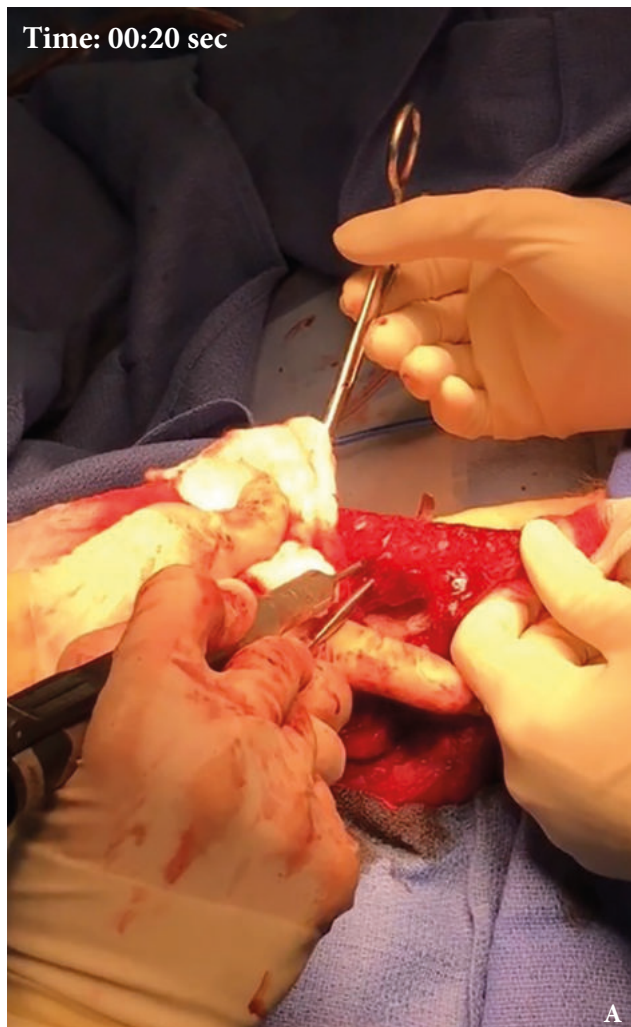So, in our case we were guided by recommendations of the Korean authors.³⁴

IMPROVING MEAN ISCHEMIA TIME

Reducing operative time is always the crucial goal upon surgical procedures. It's become especially important in cases of using transplants. **Berggren** et al, 1982 in their study "The effect of prolonged ischemia time on osteocyte and osteoblast survival in composite bone grafts revascularized by microvascular anastomoses" stated that osteocytes, and the osteoblasts could completely survive up to 25 hours of ischemia.³⁵ Despite of that fact, reducing operating time is always one of the main objectives. And reducing mean ischemia time is significantly better (up to 99 min) when using CAD/CAM comparing with conventional techniques (up to 120-180 min) (**Kääriäinen** et al, 2016).³⁶

SURGICAL PROCEDURE

After resection of the radiation injured mandibular



VIDEO. Supplemental Video Content demonstrates surgical stages: (A) cutting of the fibula grafts, (B) harvesting of the segmented grafts from left fibula. Vascular pedicle is indicated by *arrow*, skin paddle – by *arrowhead*. Video is available in the page of the full-text article on dtjournal.org and in the YouTube channel, available at https://youtu.be/_Tv8Cbt-HCA

Total video`s duration: 1 min 13 sec.

Video includes remarks of a surgeon (Todd Hanna).



QR code leads to that video at
Journal`s YouTube channel
Video DTJournal

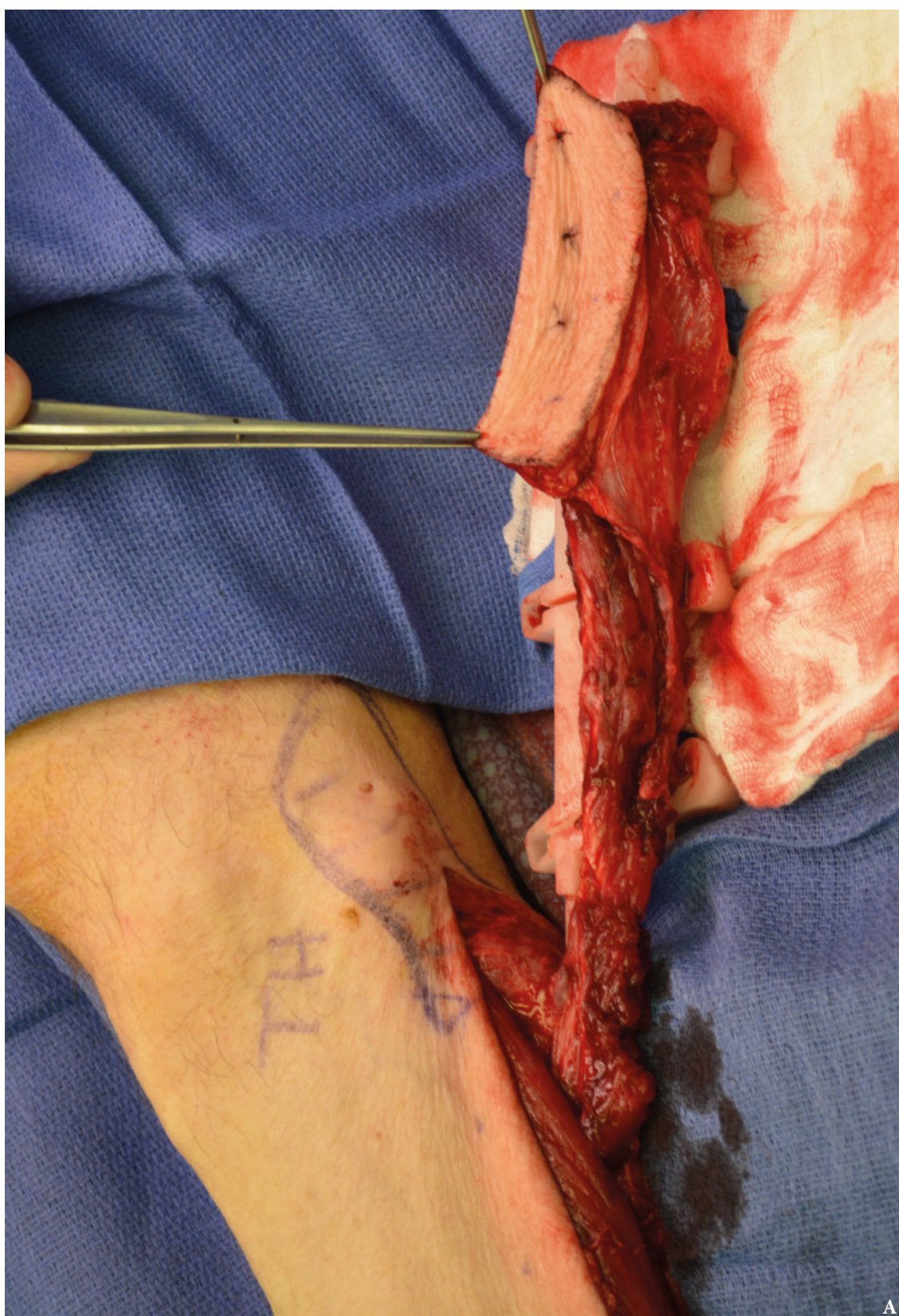


FIGURE 4. Intraoperative fibula view shows: (A) the CAD-CAM generated osteotomy guides and a whole length of harvested fibula osteocutaneous transplant. (Fig 4 continued on next page.)

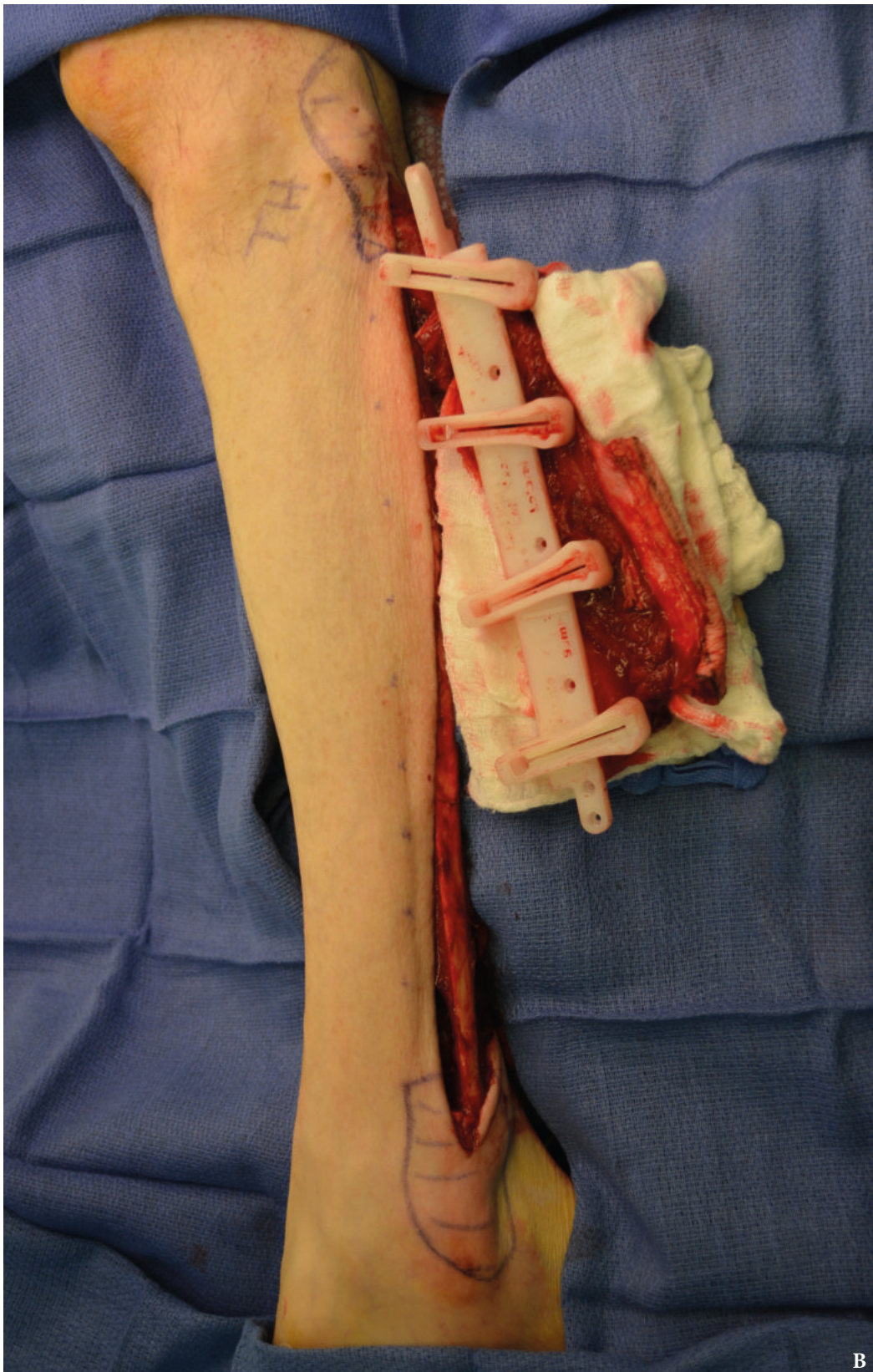


FIGURE 4 (cont'd). Intraoperative fibula view shows: **(B)** precise result of using the CAD-CAM generated osteotomy guides on the left fibula.

bone segments, the lateral segmental mandibular bony defects with a limited soft tissue defect were achieved. Reestablishing vascular supply to the preserved anterior mandibular segment was done by leaving the mucosal and muscular attachments (mylohyoid muscle and genioglossus muscle).

TAILORING OF THE FLAP & OSTEOTOMIES

We used a CAD-CAM generated osteotomy guides to perform a precise guided fibular wedge osteotomies. Each fibula segment should not be cut smaller than 3 cm (Schrag et al, 2006).¹⁴

SEGMENTS INSETTING

Inferior fibular bone segment was inlayed to the right-side mandibular defect (Fig 5A) and superior fibular bone segment was inlayed to the opposite-side defect (Fig 5B). The reconstruction plate was placed at the defects, along the inferior border of the both mandibular rami and symphysis (Fig 5C). Three bicortical screws were used on the right rami, 3 screws – on the left rami, and 4 screws – on the symphyseal bone fragment. But the fibula grafts were fixed to the plate using only monocortical screws to avoid vascular pedicle injury.¹⁶

RECIPIENT & DONOR VESSELS PREPARING

Shetawi and Buchbinder in the chapter *Mandibular Reconstruction*¹⁶ emphasize, that importance of the recipient vessel exploration cannot be ignored according to the next requirements:

1. To plan the type of free flap.
2. To plan the orientation of the flap during inset.
3. To plan the need for interpositional vein grafts.

ARTERIAL & VENOUS ANASTOMOSIS

After completing the step of inseting we start to perform next steps, making: 1) arterial anastomosis and 2) venous anastomosis. Both are performed using circumferential 9-0 or 10-0 nylon sutures. A brisk pulsatile bleeding is a right sign of a correctly performed arterial anastomosis.¹⁶ Tension or kinking is contraindicated upon laying the pedicle.

Shetawi and Buchbinder insist that it is possible to avoid hematoma formation or infections by making a proper drainage of the neck. According to the recommendation of the authors¹⁶ two different drainage systems can be used:

1. Open (Penrose) – is a soft, flexible rubber tube.
2. Closed (Pratt; *synonym*: Jackson-Pratt) – is an internal vacuum drain connected to a grenade-shaped bulb via plastic tubing.

In our case in the postoperative period we used Penrose drainage in submental region and the Pratt bilateral suction drains (Fig 6).

BASAL & ALVEOLAR BONE RECONSTRUCTION

The fact that the fibula segments' height is not enough to reconstruct simultaneously the basal and alveolar bone dictate us to choose one of the next techniques, which allows to restore alveolar bone height:

1. To inset fibula segment 1 cm above the mandibular inferior border.¹⁶
2. Symphyseal reconstruction is a perfect area to use double-barrel method.¹⁶
3. Vertical distraction is also an option to build an alveolar height.¹⁶ But the study of Lizio et al reported that cumulative success rate of the implants inserted into distracted fibula segment at the end of follow-up was only 52%.³⁷
4. Onlay grafting.³⁷

POSTOPERATIVE CARE FEATURES

The feeding tube is strongly recommended in the postoperative period with next purposes:¹⁶

1. To ensure healing.
2. To minimize breakdown of the wound and salivary leak.

PREVENTING COMPLICATIONS

Among possible complications in elderly patients the attention should be paid to delirium. This was the most common postoperative medical complication in 18 percent of cases in the report of Yang et al³⁸ and 35.3 percent of cases in the study of Sugiura et

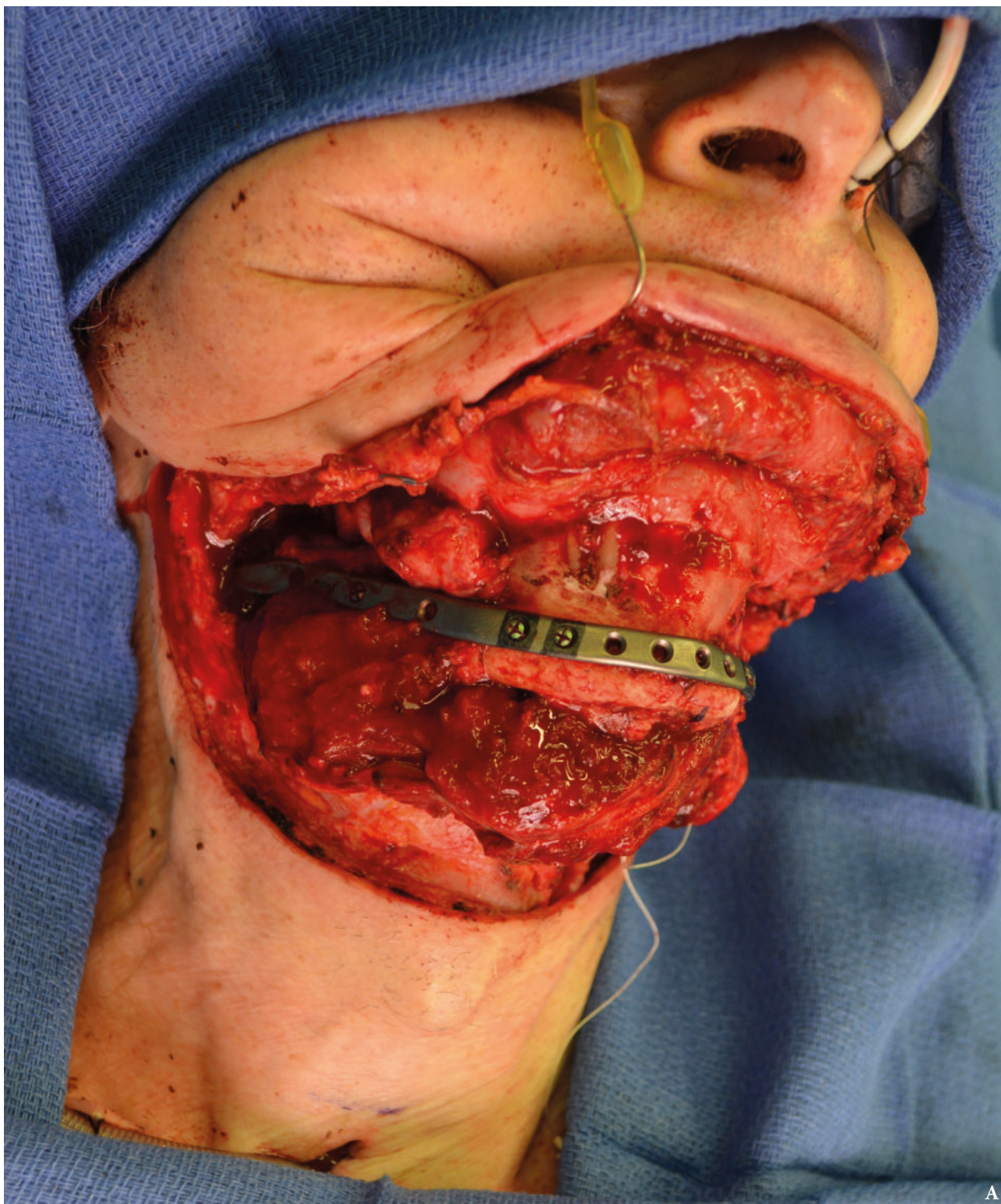

FIGURE 5. Intraoperative right lateral view (A) after fixation of harvested fibula grafts on the bilateral mandibular defects using titanium reconstructive plate. (Fig 5 continued on next page.)

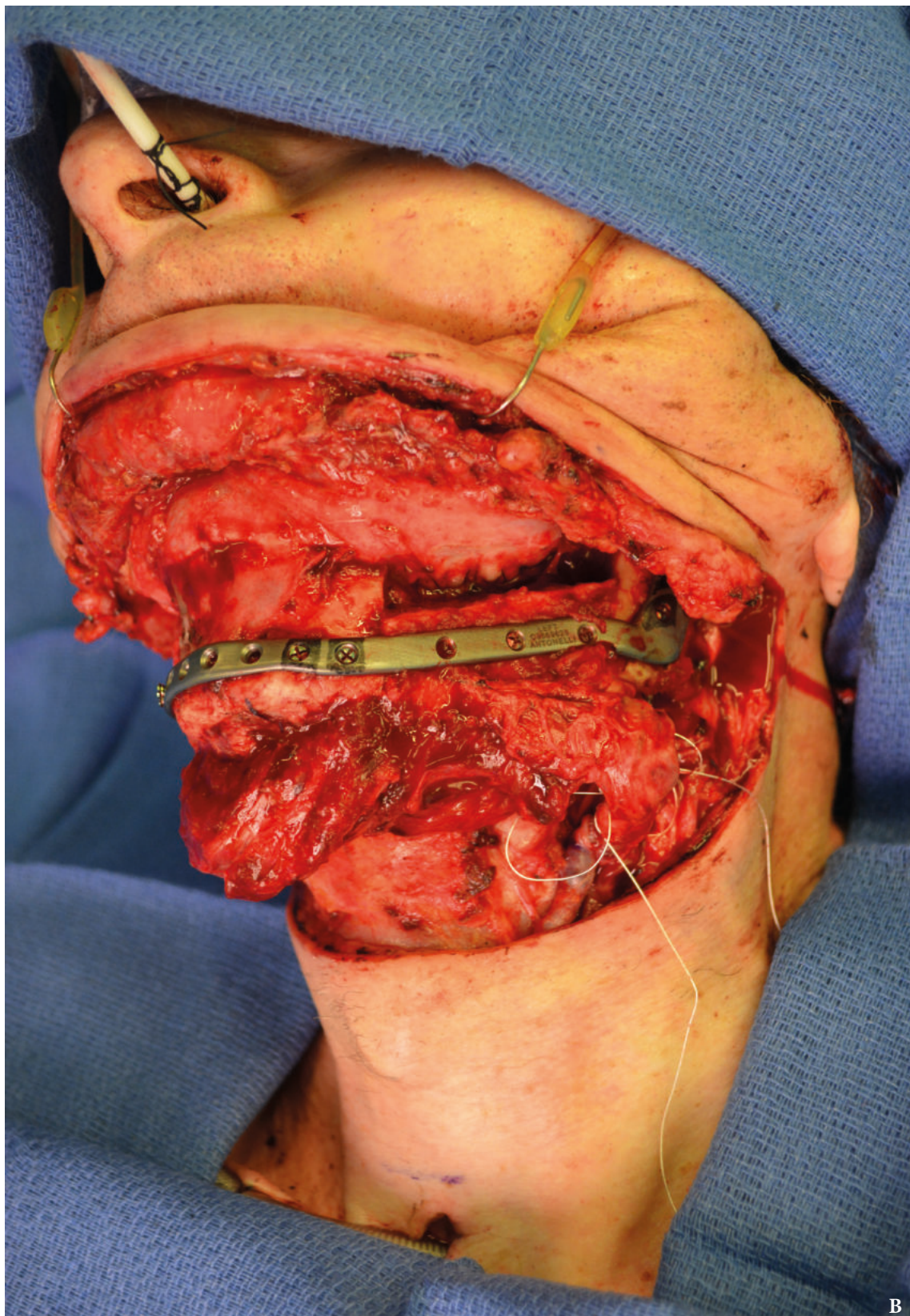


FIGURE 5 (cont'd). Intraoperative left lateral view (**B**) after fixation of harvested fibula grafts on the bilateral mandibular defects using titanium reconstruction plate. (**Fig 5 continued on next page.**)

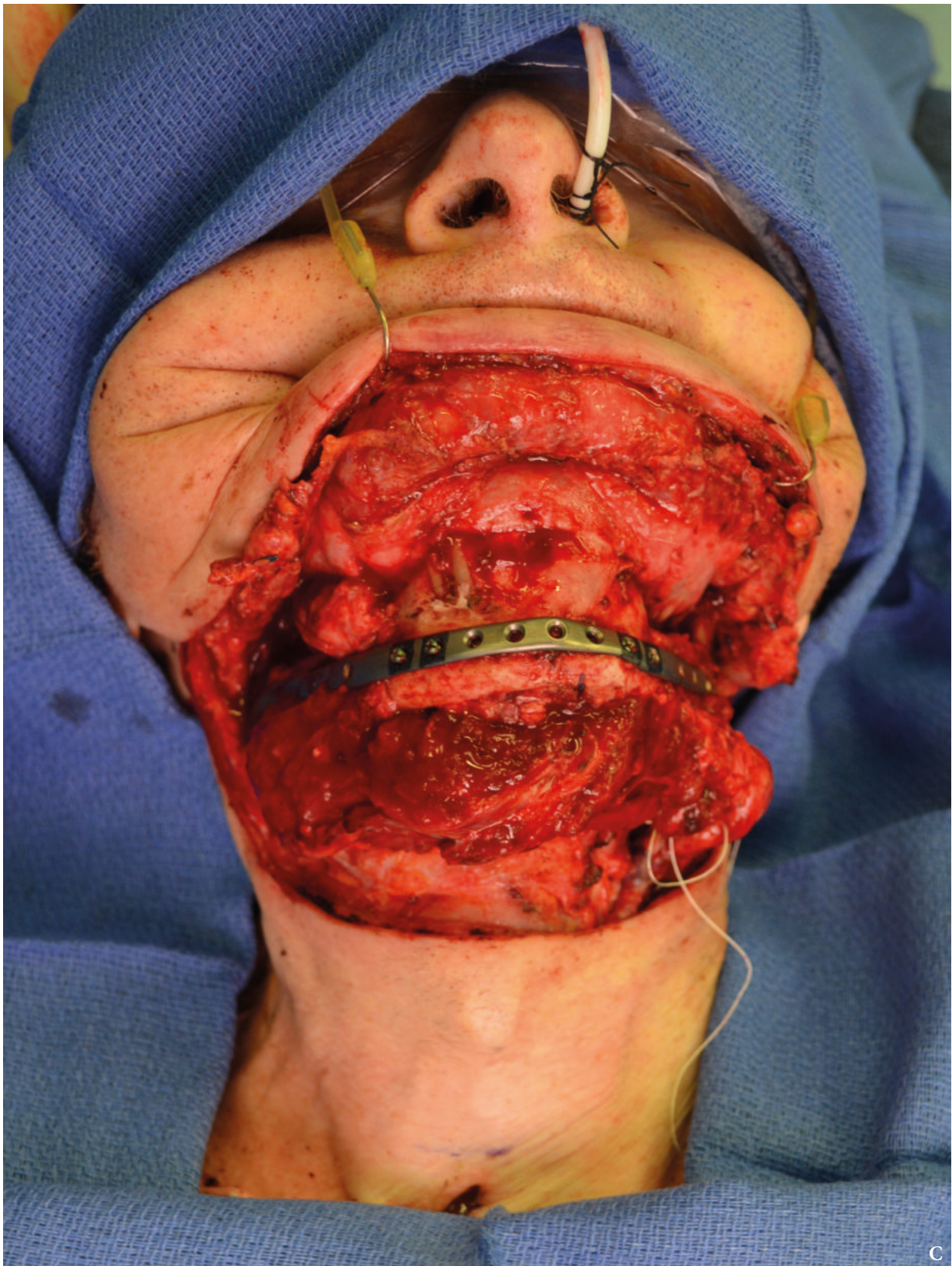

FIGURE 5 (cont'd). Intraoperative anterior view (C) after fixation of harvested fibula grafts on the bilateral mandibular defects using titanium reconstruction plate.

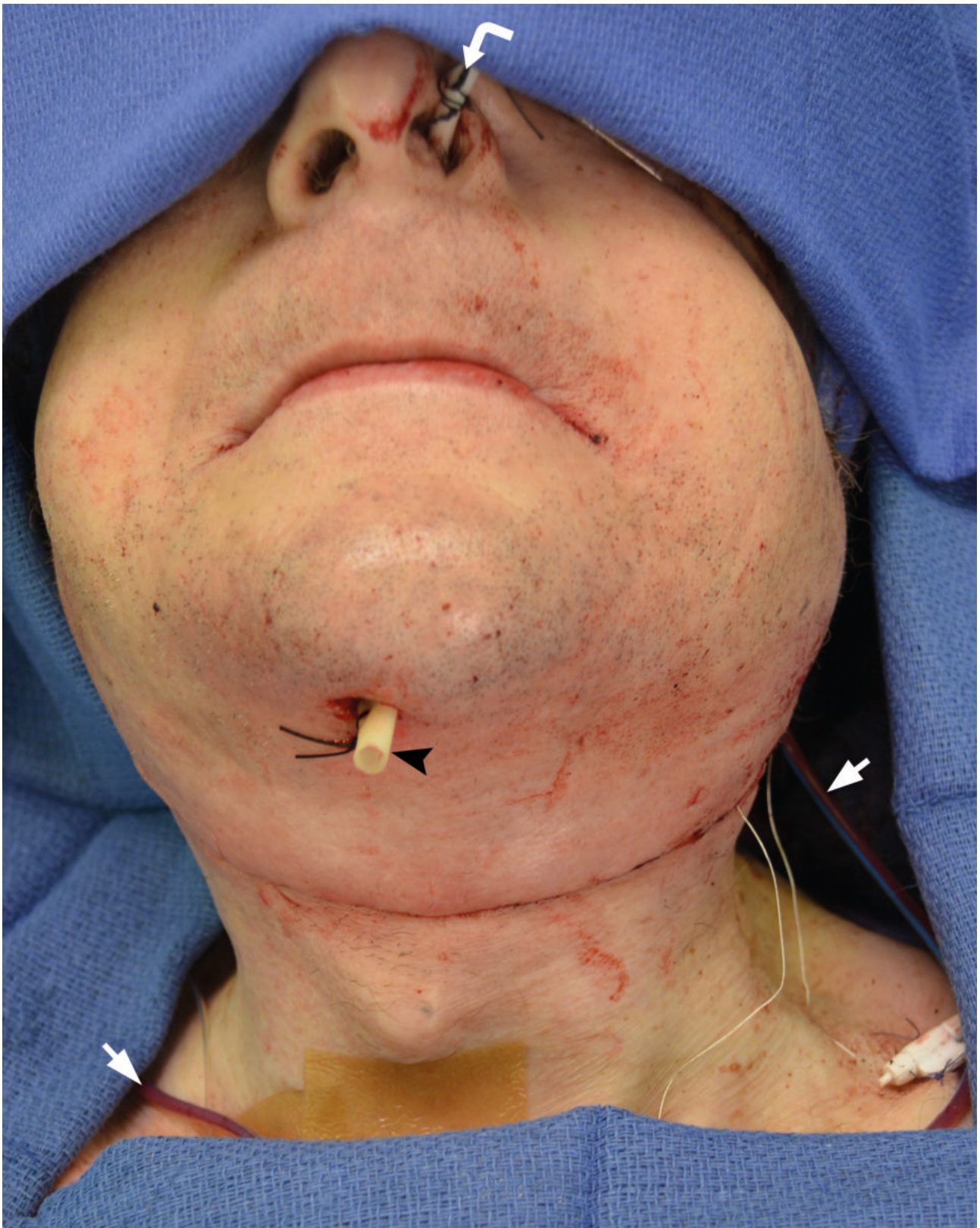

FIGURE 6. Postoperative view immediately after suturing and fixation of a Penrose rubber tubular drain (*arrowhead*) in submental region, and the Pratt vacuum suction drains (*arrows*). Feeding tube is indicated by *curved arrow*.

BILATERAL SEGMENTAL MANDIBULAR RECONSTRUCTION

al.³⁹ Our successful case of BSMR proved the results (in seventy-three ≥ 80 -year-old patients) of Sugiura et al³⁹ who suggested that elderly patients tolerate free fibula flap reconstruction. Despite of that, the authors stated that recovery of masticatory function looks difficult, even after performing free fibula flap reconstructive surgeries.³⁹

OUTCOME EVALUATION

The present surgical report is comparable to state of the art cases in the literature (Hsu et al, 2011; Chen et al, 2018; Weitz et al, 2018).^{40, 9, 41} Postoperative control of reconstruction with 3D-CT showed a perfect position of the transplanted segments (Fig 7). A patient showed success, with excellent flap vitality, nice donor site healing and simple postoperative period despite of the age. 6-month follow-up (Fig 8)

shows no signs of complications.

Thus, making the simultaneous bilateral segmental mandibular reconstruction a state of the art procedure is possible only in case of making its` every step (Fig 9) as perfect as possible according to the latest research data.

CONFLICT OF INTERESTS

The authors declare no conflict of interest.

ROLE OF CO-AUTHORS

The authors are equally contributed to that paper.

FUNDINGS

No funding was received for this study.

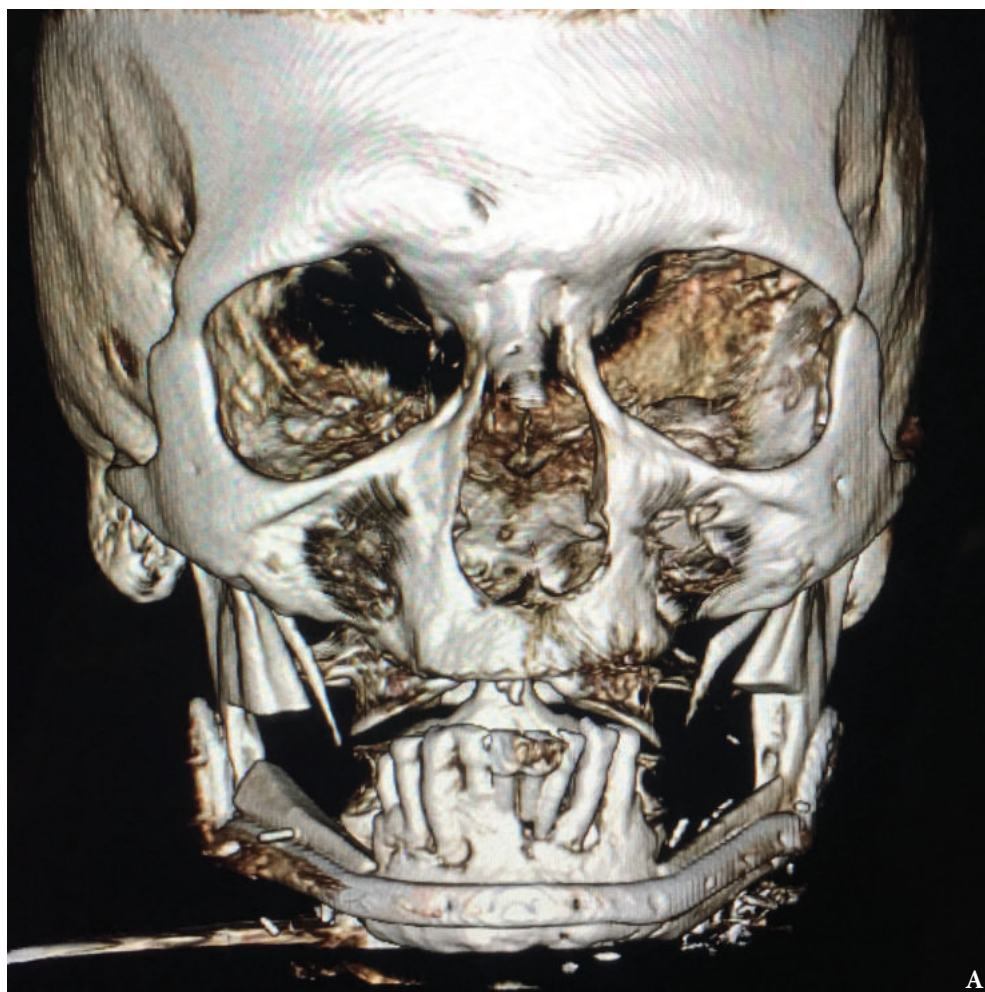

FIGURE 7. Postoperative control of reconstruction with 3D-CT: Anterior view (A). (Fig 7 continued on next page.)

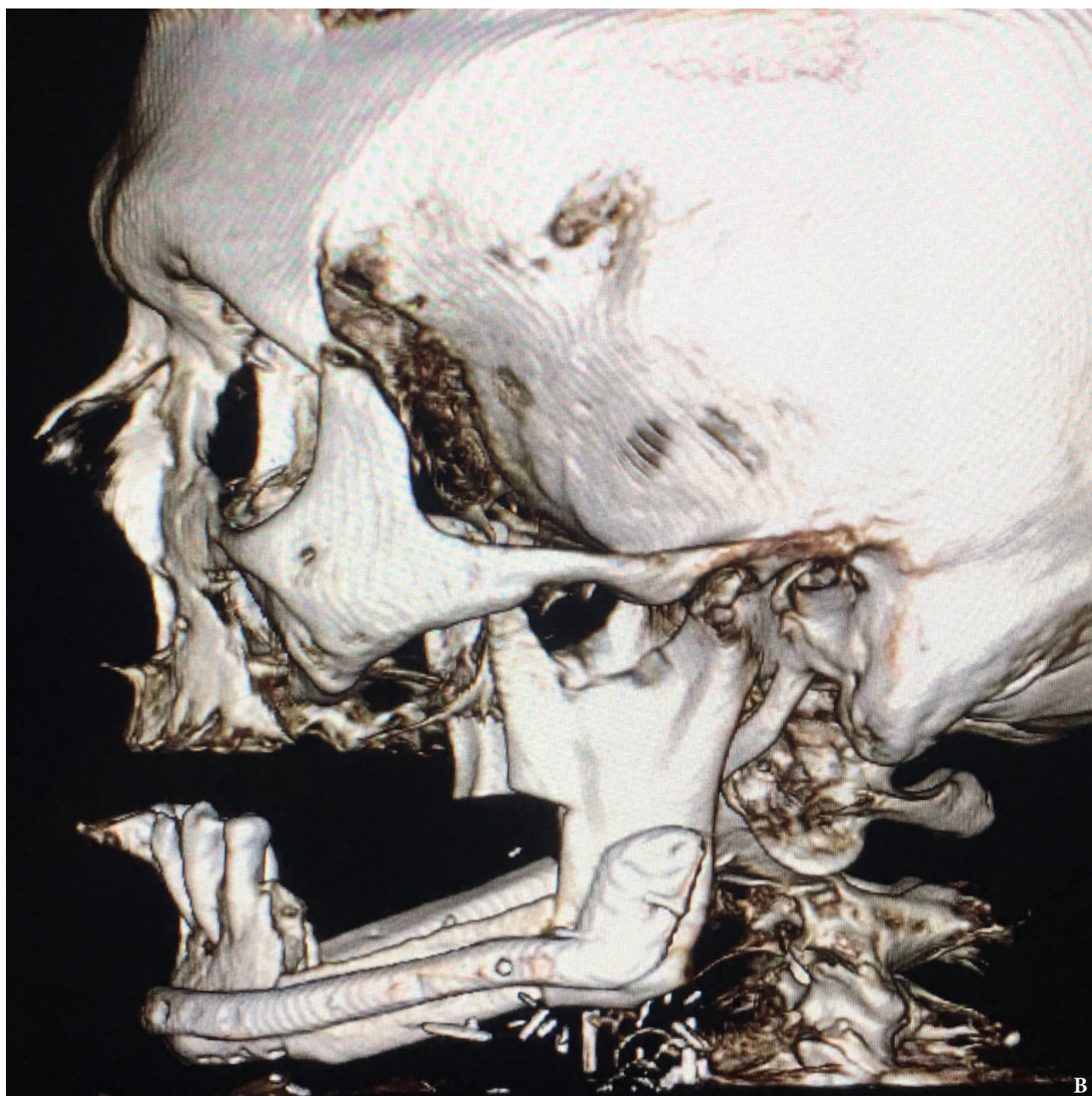


FIGURE 7 (cont'd). Postoperative control of reconstruction with 3D-CT: Left lateral view (B). (Fig 7 continued on next page.)

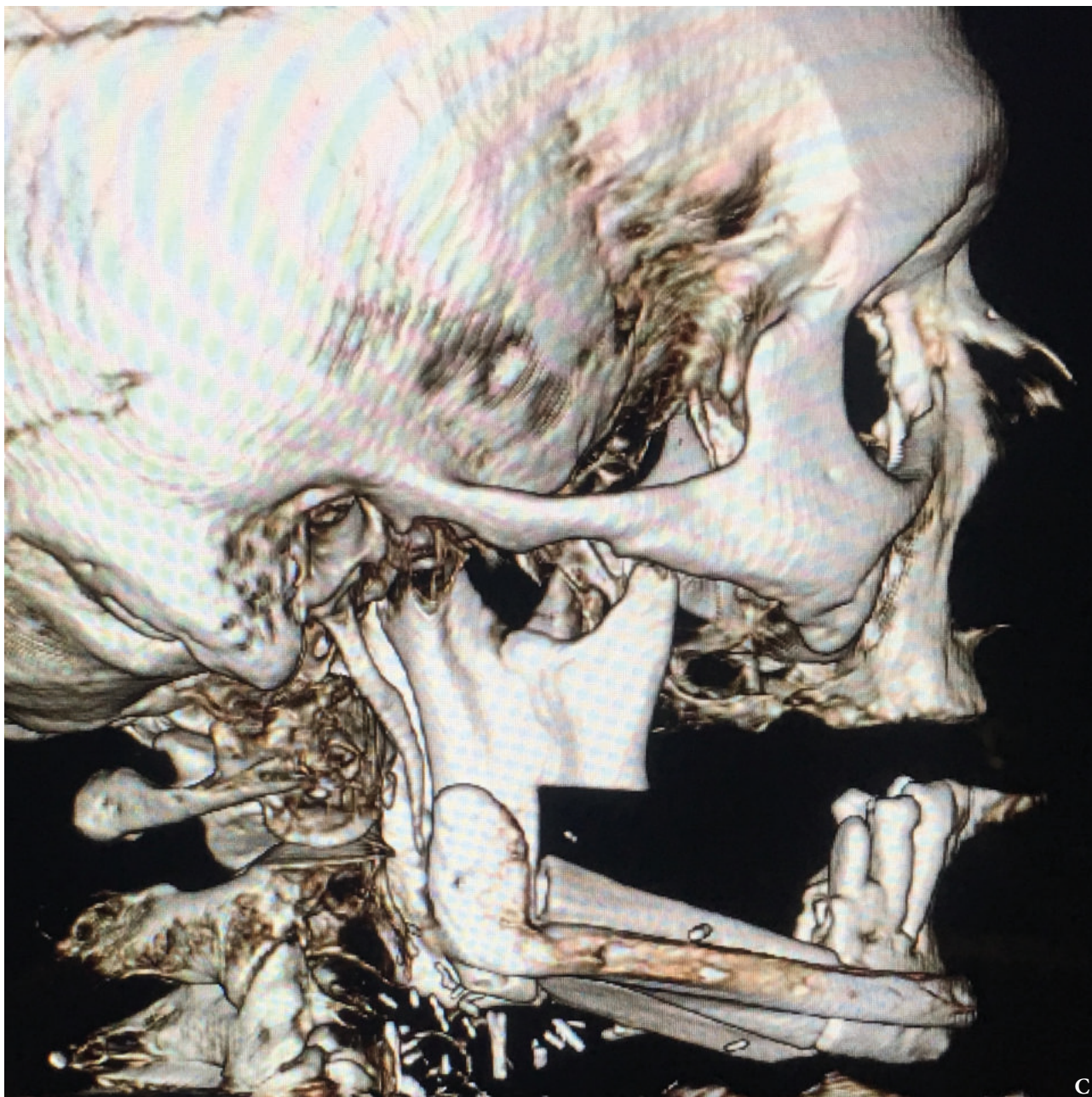


FIGURE 7 (cont'd). Postoperative control of reconstruction with 3D-CT: Right lateral view (C). (Fig 7 continued on next page.)

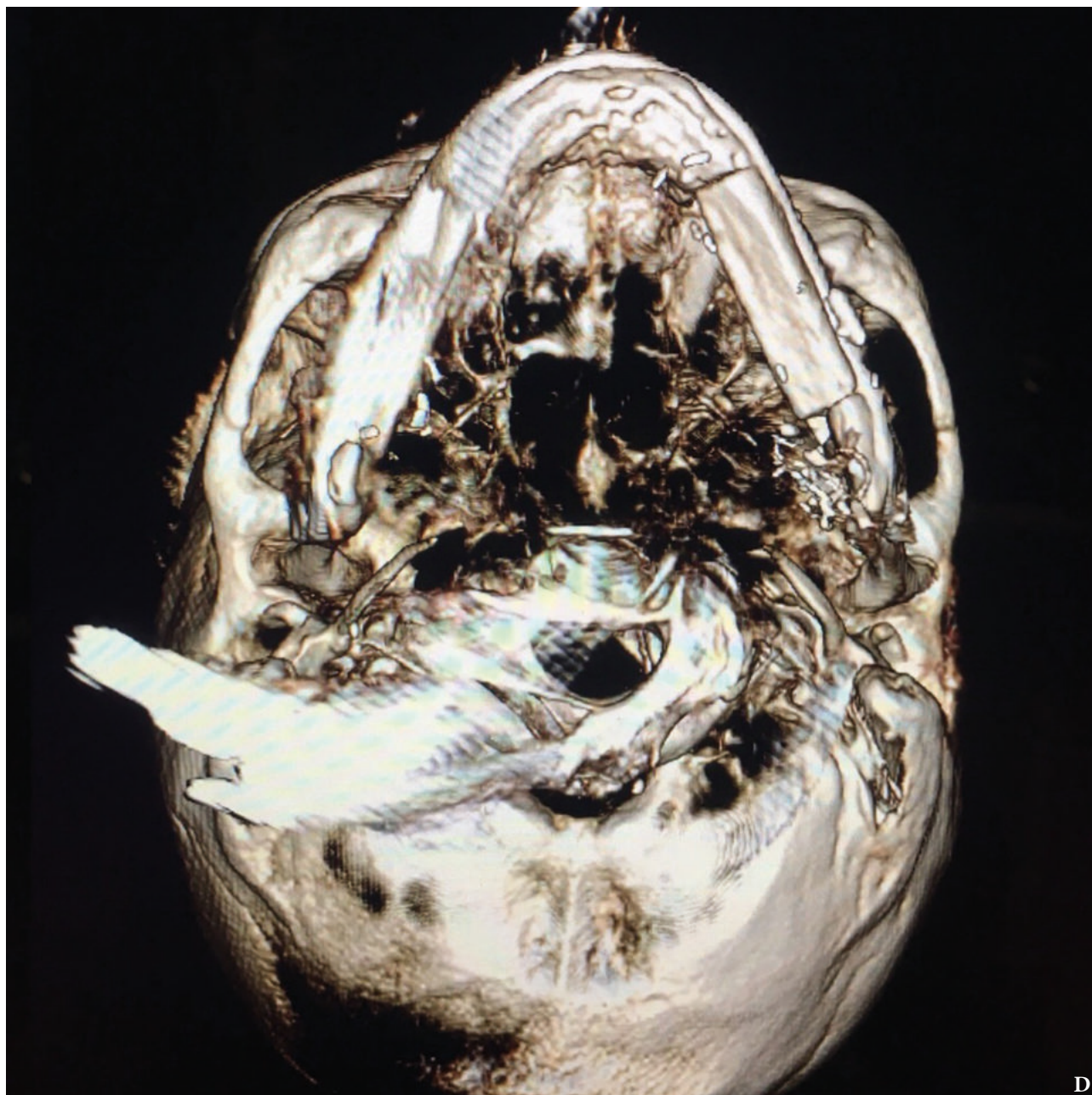


FIGURE 7 (cont'd). Postoperative control of reconstruction with 3D-CT: Axial view (**D**).

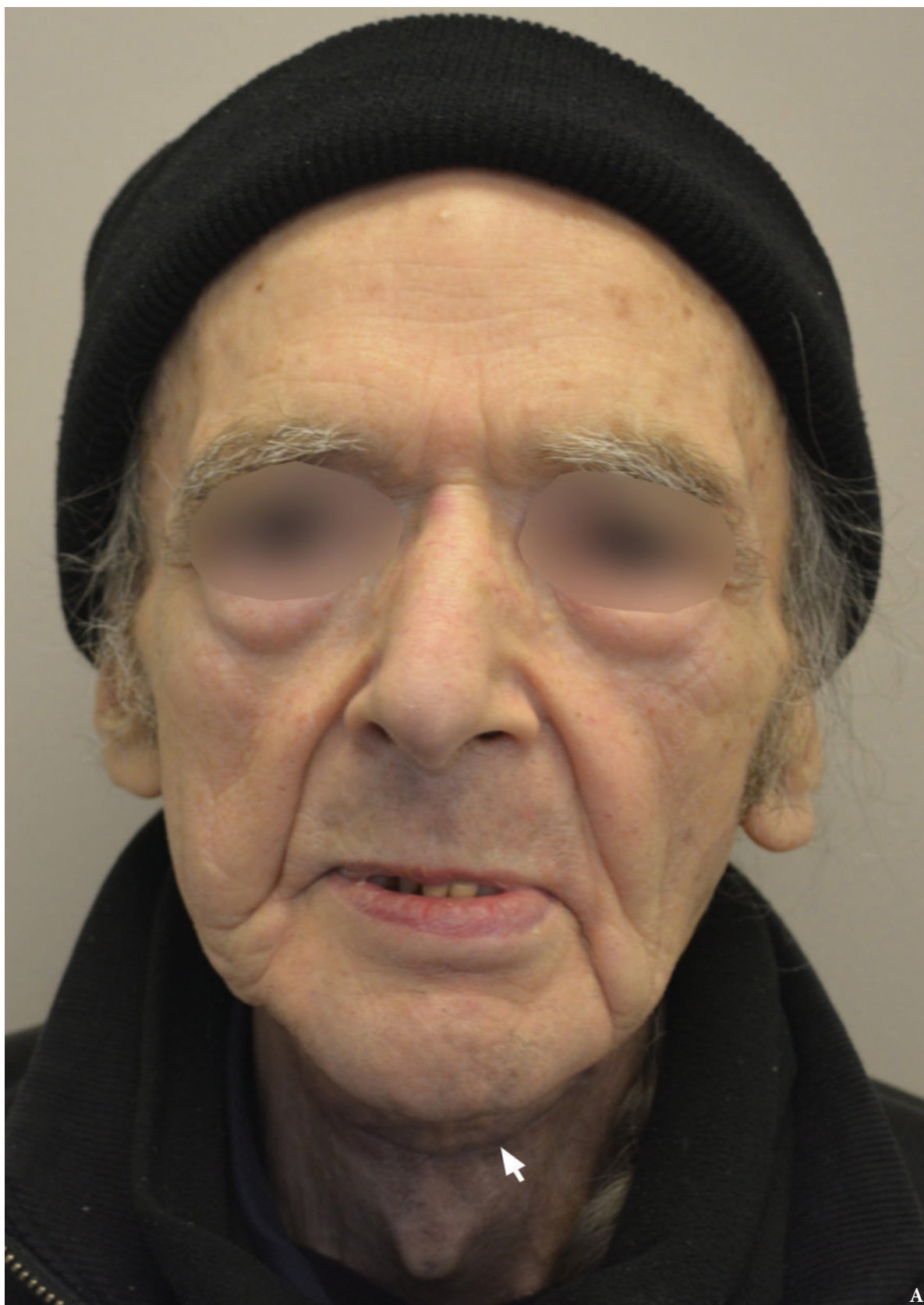

FIGURE 8. 6-month follow-up: Anterior view (A). A gentle scar (*arrow*) is hidden in the natural folds of the neck. (Fig 8 continued on next page.)

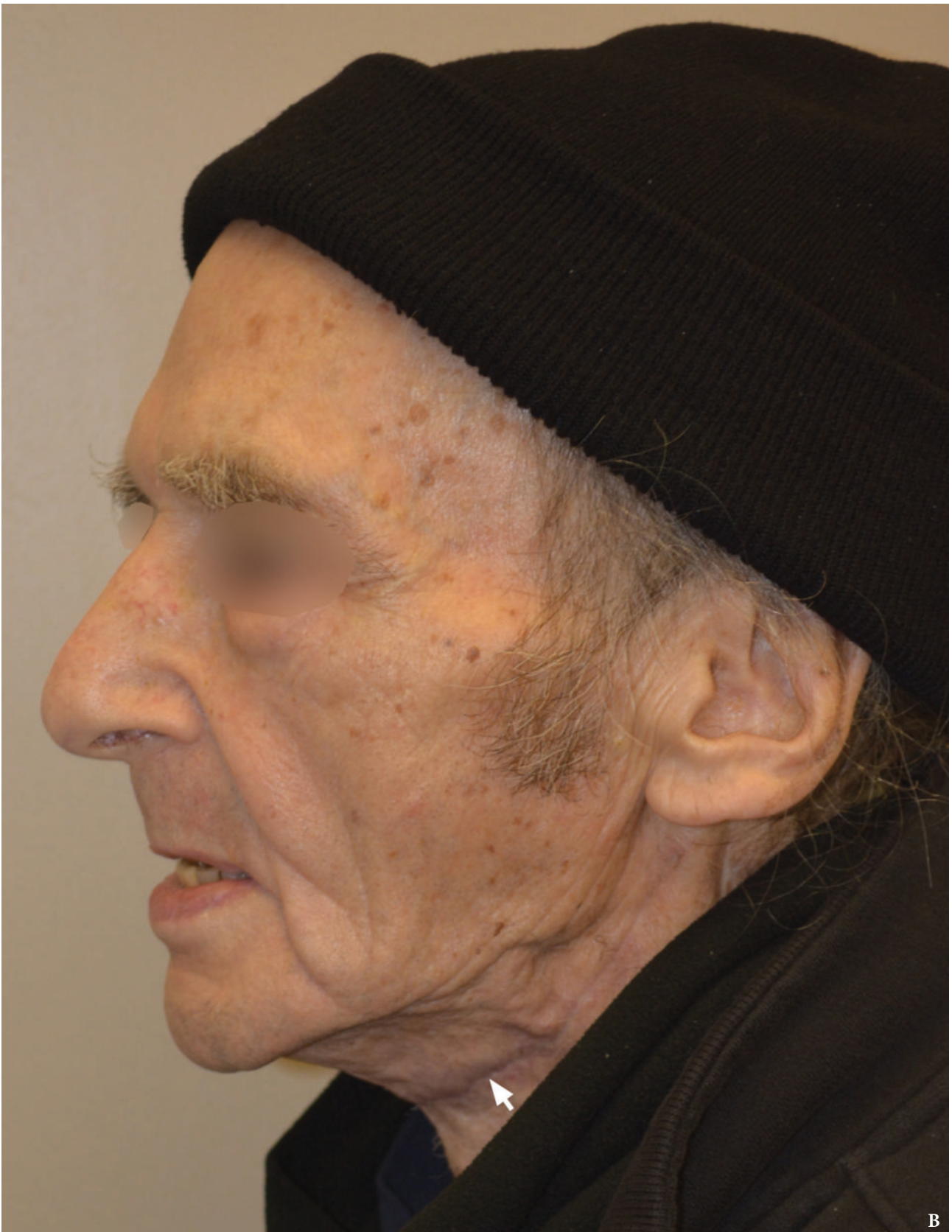

FIGURE 8 (cont'd). 6-month follow-up: Left lateral view (**B**). A gentle scar (*arrow*) is hidden in the natural folds of the neck.

BILATERAL SEGMENTAL MANDIBULAR RECONSTRUCTION

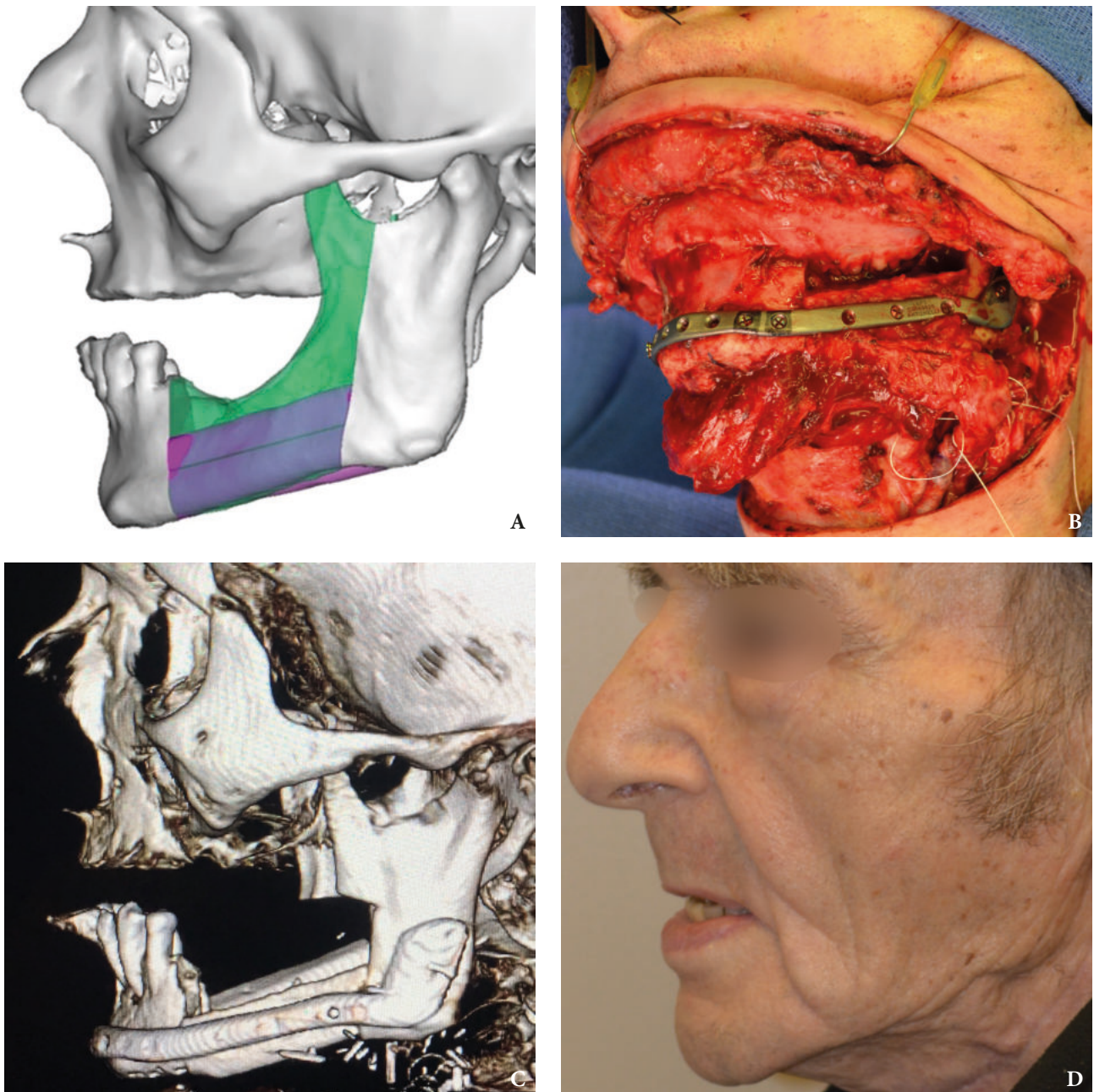


FIGURE 9. Consecutive images are illustrating the stages of the bilateral segmental mandibular reconstruction: Preoperative 3D planning (A), intraoperative view after fibular graft inlay and reconstructive plate fixation (B), postoperative CT view (C), and 6-month follow-up photography (D).

REFERENCES

1. Hidalgo DA. Fibula free flap: a new method of mandible reconstruction. *Plast Reconstr Surg* **1989**;84(1):71–9.
2. Qaisi M, Kolodney H, Swedenburg G, Chandran R, Caloss R. Fibula jaw in a day: state of the art in maxillofacial reconstruction. *J Oral Maxillofac Surg* **2016**;74(6):1284.e1–1284.e15. <https://doi.org/10.1016/j.joms.2016.01.047>.
3. Su T, Fernandes RP. Microvascular reconstruction of the mandible: an argument for the fibula osteocutaneous free flap. *Revista Española de Cirugía Oral y Maxilofacial* **2014**;36(2):1–8. <https://doi.org/10.1016/j.maxilo.2012.06.002>.
4. Fernandes RP, Quimby A, Salman S. Comprehensive reconstruction of mandibular defects with free fibula flaps and endosseous implants. *J Diagn Treat Oral Maxillofac Pathol* **2017**;1(1):6–10. <https://doi.org/10.23999/j.dtop.2017.1.1>.
5. Reychler H, Iriarte Ortabe J, Lambert F. Bilateral mandibular angle reconstruction with a single free vascularised fibula flap. *Plast Reconstr Surg* **1997**;99(5):1411–4.
6. Bianchi B, Copelli C, Ferrari S, Ferri A, Sesenna E. Bilateral mandibular reconstruction with a single vascularised fibula flap. A case report. *J Plast Reconstr Aesthet Surg* **2008**;61(10):1252–4. <https://doi.org/10.1016/j.bjps.2007.12.056>.
7. Mello-Filho FV, Brigato RR, Eichenberger GC, Xavier SR, Mamede RC. Reconstruction of two defects with one fibular flap. *Am J Otolaryngol* **2008**;29(3):218–21. <https://doi.org/10.1016/j.amjoto.2007.07.003>.
8. Jacobson AS, Buchbinder D, Urken ML. Reconstruction of bilateral osteoradionecrosis of the mandible using a single fibular free flap. *Laryngoscope* **2010**;120(2):273–5. <https://doi.org/10.1002/lary.20717>.
9. Chen R, Zhang HQ, Huang ZX, Li SH, Zhang DM, Huang ZQ. Computer-assisted resection and reconstruction of bilateral osteoradionecrosis of the mandible using 2 separate flaps prepared from a single fibula. *Oral Surg Oral Med Oral Pathol Oral Radiol* **2018**;126(2):102–6. <https://doi.org/10.1016/j.oooo.2018.02.019>.
10. Ekanayake K, Thomas DG, Brennan PA. Reconstruction of a bilateral mandibular defect due to trauma using a single fibula free flap. *J Oral Maxillofac Surg* **2013**;71(10):1724–8. <https://doi.org/10.1016/j.joms.2013.06.195>.
11. Tymofieiev OO. Manual of maxillofacial and oral surgery [Russian]. 5th ed. Kyiv: Chervona Ruta-Turs; **2012**.
12. Tymofieiev OO, Tymofieiev OO. Osteoradionecrosis of the jaws: report of nineteen consecutive cases. *J Diagn Treat Oral Maxillofac Pathol* **2018**;2(1):51–6. <http://dx.doi.org/10.23999/j.dtop.2018.2.5>.
13. Chronopoulos A, Zarra T, Ehrenfeld M, Otto S. Osteoradionecrosis of the jaws: definition, epidemiology, staging and clinical and radiological findings. A concise review. *Int Dent J* **2018**;68(1):22–30. <https://doi.org/10.1111/idj.12318>.
14. Schrag C, Chang Y-M, Tsai C-Y, Wei F-C. Complete rehabilitation of the mandible following segmental resection. *J Surg Oncol* **2006**;94(6):538–45. <https://doi.org/doi:10.1002/jso.20491>.
15. Bae DS, Waters PM. Free vascularized fibula grafting: principles, techniques, and applications in pediatric orthopaedics. [www.orthojournalhms.org/volume 8:1–4](http://www.orthojournalhms.org/volume%208%3A1-4).
16. Kuriakose MA. Contemporary oral oncology: oral and maxillofacial reconstructive surgery. 1st ed. Cham: Springer; **2017**. <https://doi.org/10.1007/978-3-319-43857-3>.
17. Jewer DD, Boyd JB, Manktelow RT, Zuker RM, Rosen IB, Gullane PJ, Rotstein LE, Freeman JE. Orofacial and mandibular reconstruction with the iliac crest free flap: a review of 60 cases and a new method of classification. *Plast Reconstr Surg* **1989**;84(3):391–403; discussion 404–5.
18. Lapis PN, DeLacure MD, Givi B. Factors in successful elimination of elective tracheotomy in mandibular reconstruction with microvascular tissue. *JAMA Otolaryngol Head Neck Surg* **2016**;142(1):46–51. <https://doi.org/10.1001/jamaoto.2015.2845>.
19. Crosher R, Baldie C, Mitchell R. Selective use of tracheostomy in surgery for head and neck cancer: an audit. *Br J Oral Maxillofac Surg* **1997**;35(1):43–5.
20. Lin HS, Wang D, Fee WE, Goode RL, Terris DJ. Airway management after maxillectomy: routine tracheostomy is unnecessary. *Laryngoscope* **2003**;113(6):929–32. <https://doi.org/10.1097/00005537-200306000-00002>.
21. Kruse-Lösler B, Langer E, Reich A, Joos U, Kleinheinz J. Score system for elective tracheotomy in major head and neck tumour surgery. *Acta Anaesthesiol Scand* **2005**;49(5):654–9. <https://doi.org/10.1111/j.1399-6576.2005.00655.x>.
22. Cameron M, Corner A, Diba A, Hankins M. Development of a tracheostomy scoring system to guide airway management after major head and neck surgery. *Int J Oral Maxillofac Surg* **2009**;38(8):846–9. <https://doi.org/10.1016/j.ijom.2009.03.713>.
23. Coyle MJ, Shrimpton A, Perkins C, Fasanmade A, Godden D. First do no harm: should routine tracheostomy after oral and maxillofacial oncological operations be abandoned? *Br J Oral Maxillofac Surg* **2012**;50(8):732–5. <https://doi.org/10.1016/j.bjoms.2012.01.003>.

24. Brickman DS, Reh DD, Schneider DS, Bush B, Rosenthal EL, Wax MK. Airway management after maxillectomy with free flap reconstruction. *Head Neck* **2013**;35(8):1061–5. <https://doi.org/10.1002/hed.23082>.
25. Coyle MJ, Tyrrell R, Godden A, Hughes CW, Perkins C, Thomas S, Godden D. Replacing tracheostomy with overnight intubation to manage the airway in head and neck oncology patients: towards an improved recovery. *Br J Oral Maxillofac Surg* **2013**;51(6):493–6. <https://doi.org/10.1016/j.bjoms.2013.01.005>.
26. Meerwein C, Pezier TF, Beck-Schimmer B, Schmid S, Huber GF. Airway management in head and neck cancer patients undergoing microvascular free tissue transfer: delayed extubation as an alternative to routine tracheotomy. *Swiss Med Wkly* **2014**;144:w13941. <https://doi.org/0.4414/smw.2014.13941>.
27. Moubayed SP, Barker DA, Razfar A, Nabili V, Blackwell KE. Microvascular reconstruction of segmental mandibular defects without tracheostomy. *Otolaryngol Head Neck Surg* **2015**;152(2):250–4. <https://doi.org/10.1177/0194599814556625>.
28. Stathopoulos P, Stassen L. A modification of the Bjork flap in tracheostomies for head and neck cancer patients. *J Stomatol Oral Maxillofac Surg* **2018**;119(5):444–5. <https://doi.org/10.1016/j.jormas.2018.04.018>.
29. Wolff K-D, Hölzle R. Raising of microvascular flaps: a systematic approach. 2nd ed. Cham: Springer; **2011**. <https://doi.org/10.1007/978-3-642-13831-7>.
30. Wittwer G, Adeyemo WL, Turhani D, Ploder O. Treatment of atrophic mandibular fractures based on the degree of atrophy— experience with different plating systems: a retrospective study. *J Oral Maxillofac Surg* **2006**;64(2):230–4. <https://doi.org/10.1016/j.joms.2005.10.025>.
31. Bao T, He J, Yu C, Zhao W, Lin Y, Wang H, Liu J, Zhu H. Utilization of a pre-bent plate-positioning surgical guide system in precise mandibular reconstruction with a free fibula flap. *Oral Oncol* **2017**;75:133–9. <https://doi.org/10.1016/j.oraloncology.2017.11.011>.
32. Mugino H, Takagi S, Oya R, Nakamura S, Ikemura K. Miniplate osteosynthesis of fractures of the edentulous mandible. *Clin Oral Investig* **2005**;9:266–70. <https://doi.org/10.1007/s00784-005-0012-5>.
33. Bujtar P, Simonovics J, Varadi K, Sandor GK, Avery CME. The biomechanical aspects of reconstruction for segmental defects of the mandible: a finite element study to assess the optimisation of plate and screw factors. *J Craniomaxillofac Surg* **2014**;42(6):855–62. <https://doi.org/10.1016/j.jcms.2013.12.005>.
34. Park SM, Lee JW, Noh G. Which plate results in better stability after segmental mandibular resection and fibula free flap reconstruction? Biomechanical analysis. *Oral Surg Oral Med Oral Pathol Oral Radiol* **2018**;126(5):380–9. <https://doi.org/10.1016/j.oooo.2018.05.048>.
35. Berggren A, Weiland AJ, Dorfman H. The effect of prolonged ischemia time on osteocyte and osteoblast survival in composite bone grafts revascularized by microvascular anastomoses. *Plast Reconstr Surg* **1982**;69(2):290–8.
36. Kääriäinen M, Kuuskeri M, Gremoutis G, Kuokkanen H, Miettinen A, Laranne J. Utilization of three-dimensional computer-aided preoperative virtual planning and manufacturing in maxillary and mandibular reconstruction with a microvascular fibula flap. *J Reconstr Microsurg* **2016**;32(2):137–41. <https://doi.org/10.1055/s-0035-1563396>.
37. Lizio G, Corinaldesi G, Pieri F, Marchetti C. Problems with dental implants that were placed on vertically distracted fibular free flaps after resection: a report of six cases. *Br J Oral Maxillofac Surg* **2009**;47(6):455–60. <https://doi.org/10.1016/j.bjoms.2009.06.002>.
38. Yang R, Lubek JE, Dyalram D, Liu X, Ord RA. Head and neck cancer surgery in an elderly patient population: a retrospective review. *Int J Oral Maxillofac Surg* **2014**;43(12):1413–7. <https://doi.org/10.1016/j.ijom.2014.08.008>.
39. Sugiura Y, Sarukawa S, Hayasaka J, Kamochi H, Noguchi T, Mori Y. Mandibular reconstruction with free fibula flaps in the elderly: a retrospective evaluation. *Int J Oral Maxillofac Surg* **2018**;47(8):983–9. <https://doi.org/10.1016/j.ijom.2018.02.009>.
40. Hsu WK, Lo CH, Lee FH, Su WC, Lin TS, Pai H. The timing of tracheostomy extubation in head and neck cancer patients. *J Oral Maxillofac Surg* **2011**;40(10):1069. <https://doi.org/10.1016/j.ijom.2011.07.146>.
41. Weitz J, Wolff KD, Kesting MR, Nobis CP. Development of a novel resection and cutting guide for mandibular reconstruction using free fibula flap. *J Craniomaxillofac Surg* **2018**;46(11):1975–8. <https://doi.org/10.1016/j.jcms.2018.09.007>.

Hanna TC, Kraus DH.

State of the art simultaneous bilateral segmental mandibular reconstruction using a single fibula transplant: discussion of the surgical steps.

J Diagn Treat Oral Maxillofac Pathol **2019**;3(3):76–103.

<http://dx.doi.org/10.23999/j.dtomp.2019.3.2>